

Paleopathological Study of Hallux Valgus

S.A. Mays*

Ancient Monuments Laboratory, English Heritage Centre for Archaeology, Fort Cumberland, Eastney, Portsmouth PO4 9LD, UK

KEY WORDS human skeletal remains; Medieval England; podiatric health; footwear; paleopathology

ABSTRACT Hallux valgus is the abnormal lateral deviation of the great toe. The principal cause is biomechanical, specifically the habitual use of footwear which constricts the toes. In this study, descriptions of the anatomical changes of hallux valgus from published cadaveric and clinical studies were used to generate criteria for identifying the condition in ancient skeletal remains. The value of systematic scoring of hallux valgus in paleopathology is illustrated using two British skeletal series,

one dating from the earlier and one from the later Medieval period. It was found that hallux valgus was restricted to later Medieval burials. This appears consistent with archaeological and historical evidence for a rise in popularity, during the late Medieval period (at least among the richer social classes), of narrow, pointed shoes which would have constricted the toes. *Am J Phys Anthropol* 126:139–149, 2005. © 2004 Wiley-Liss, Inc.

Hallux valgus is the lateral deviation of the great toe. Although it may in some instances be congenital, the overwhelming majority of cases are acquired. The principal eliciting factor is biomechanical: the wearing of boots or shoes that constrict the toes. A number of lines of evidence support this. Hallux valgus is almost exclusively restricted to shod populations, where it is the most common orthopedic problem of the normal adult foot (Helfet and Gruebel-Lee, 1980). It is exceedingly rare in populations that are habitually barefoot (Hoffman, 1905; James, 1939; Barnett, 1962). When footwear is introduced into hitherto unshod populations, there is a sharp increase in hallux valgus among those who wear shoes (Sim-Fook and Hodgson, 1958; Shine, 1965). The frequency of hallux valgus varies with the type of footwear used. For example, its frequency increased among Japanese women during the second half of the 20th century, as loose-fitting traditional footwear was gradually replaced by more constrictive Western-style shoes (Kato and Watanabe, 1981). A study of Saudi Arabian women (Al-Abdulwahab and Al-Dosry, 2000) indicated that those without hallux valgus wore shoes with wide, round toes, whereas those with hallux valgus had shoes with narrow, pointed toes. In Britain, approximately 90% of patients with hallux valgus are female (Hardy and Clapham, 1951; Mann and Coughlin, 1981), reflecting the greater recent frequency in women's fashions of shoes which markedly constrict the toes.

In this light, the study of hallux valgus in skeletons from archaeological sites would appear to have considerable potential, both for elucidating the history of an important aspect of podiatric health, and

for helping infer something of the type of footwear used by past populations or social subgroups. Despite this, hallux valgus has received only rather cursory attention in paleopathology. The aims of the present work are to bring this condition to the attention of paleopathologists, to describe the osteological changes which permit its recognition in ancient skeletal remains, and to demonstrate the value of recording it archaeologically by means of a pilot study on British Medieval material.

ANATOMY OF THE FIRST METATARSO-PHALANGEAL ARTICULATION

The distal articular surface of the first metatarsal takes the form of a rounded prominence in its superior part, and on the plantar aspect two broad grooves are present (Fig. 1). The convex superior part of the joint surface articulates with the concave surface of the basal phalanx; each of the plantar grooves articulates with a sesamoid bone embedded in the plantar pad, a mass of dense, fibrous tissue. The plantar pad attaches the sesamoids to the base of the proximal phalanx. The medial and lateral heads of the flexor hallucis brevis insert into the medial and lateral sesamoids (Fig. 2). Immediately

*Correspondence to: S.A. Mays, Ancient Monuments Laboratory, English Heritage Centre for Archaeology, Fort Cumberland, Fort Cumberland Road, Eastney, Portsmouth PO4 9LD, UK.
E-mail: simon.mays@english-heritage.org.uk

Received 26 July 2003; accepted 5 December 2003.

DOI 10.1002/ajpa.20114
Published online 6 July 2004 in Wiley InterScience (www.interscience.wiley.com).

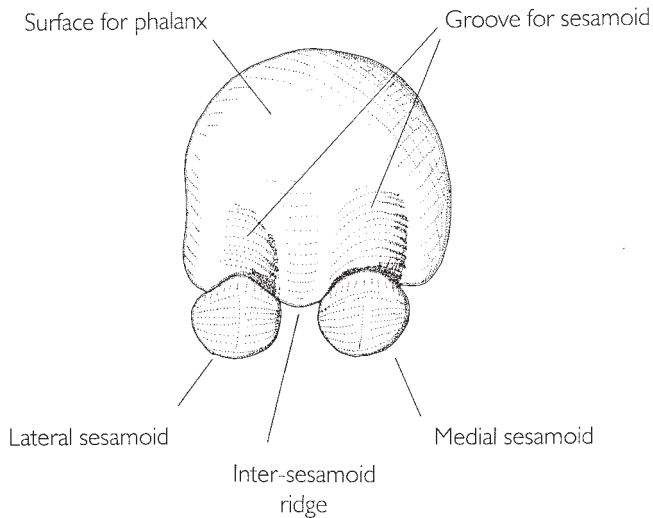


Fig. 1. Anterior view of head of right first metatarsal and associated sesamoids.

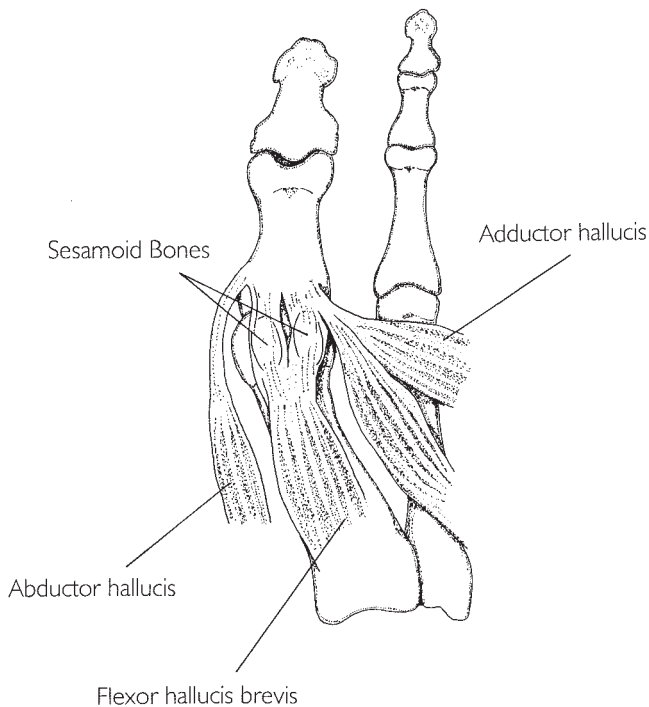


Fig. 2. Plantar musculature of great toe.

posterior to the articular surface, on the medial and lateral sides of the metatarsal head, lie two epicondyles to which are attached the medial and lateral collateral and sesamoid ligaments (Fig. 3). The collateral ligaments insert on the basal phalanx, and each sesamoid ligament inserts on the margin of the plantar pad and on a sesamoid bone. The collateral ligaments stabilize the metatarso-phalangeal joint; the sesamoid ligaments retain the sesamoids within their grooves.

The morbid anatomy of hallux valgus has been evaluated principally from observations on dissected material and on radiographs of living subjects (e.g.,

Haines and McDougall, 1954). Briefly, the lateral deflection of the great toe stretches the ligaments on the medial side of the hallucial metatarso-phalangeal joint. The tendons of the adductor hallucis and abductor hallucis, and the plantar pad, secure the sesamoid complex firmly to the basal phalanx, so that the sesamoids tend to be displaced with the digit. The sesamoid complex tends to slide off the metatarsal head so that the sesamoids are subluxated laterally. No muscles insert on the metatarsal head (Fig. 2), so its position is influenced by that of the proximal phalanx. As the phalanx is forced laterally, it pushes the metatarsal head medially, a condition known as metatarsus primus varus.

The deformation of the first metatarso-phalangeal articulation has a number of secondary effects. The metatarsal head becomes unduly prominent beneath the skin on the medial aspect of the foot. This tends to lead to chronic pressure at this point from footwear, so that in time a bursa develops, commonly known as a bunion. This may become fibrous and inflamed. The medial part of the joint capsule and the medial ligaments may become thickened (Stein, 1938; Haines and McDougall, 1954). The distortion of the joint may lead to degenerative arthritic changes (Helfet and Greubel-Lee, 1980; Weinfeld and Schon, 1998).

MATERIALS

The skeletal material used in the current investigation comes from Ipswich, Suffolk, England. The material can be split into an earlier and later Medieval group, dating to the late 9th–late 11th century AD, and the mid-13th–mid-16th century AD, respectively.

The earlier material comes from two sites, School Street and St. Peter's Street. Excavations at School Street yielded 95 burials (Mays, 1989a) of 10th–11th century AD date. The excavated area represents part of a larger burial ground. No church was located. However, given the burial practices of the time, it is likely that the burial ground was associated with a church but that this lay beyond the excavated area. Excavations at St. Peter's Street yielded 10 burials (Mays, 1989b) of late 9th–early 10th century date. They are unrelated to any formal cemetery, and appear to represent interments in the back yards of tenements.

The later material comes from the Ipswich Blackfriars site. This was also located at School Street and represents a later phase of use of the site than the 10th–11th century cemetery. Two hundred and fifty burials (Mays, 1991) were excavated. They date from the foundation of the friary in 1263, to its dissolution in 1538 by Henry VIII as part of his suppression of the monastic orders. The burials represent lay benefactors of the friary; the cemetery used for burials of the religious brethren has not been excavated.

In addition to the chronological distinction, the two groups of material also differ somewhat by so-

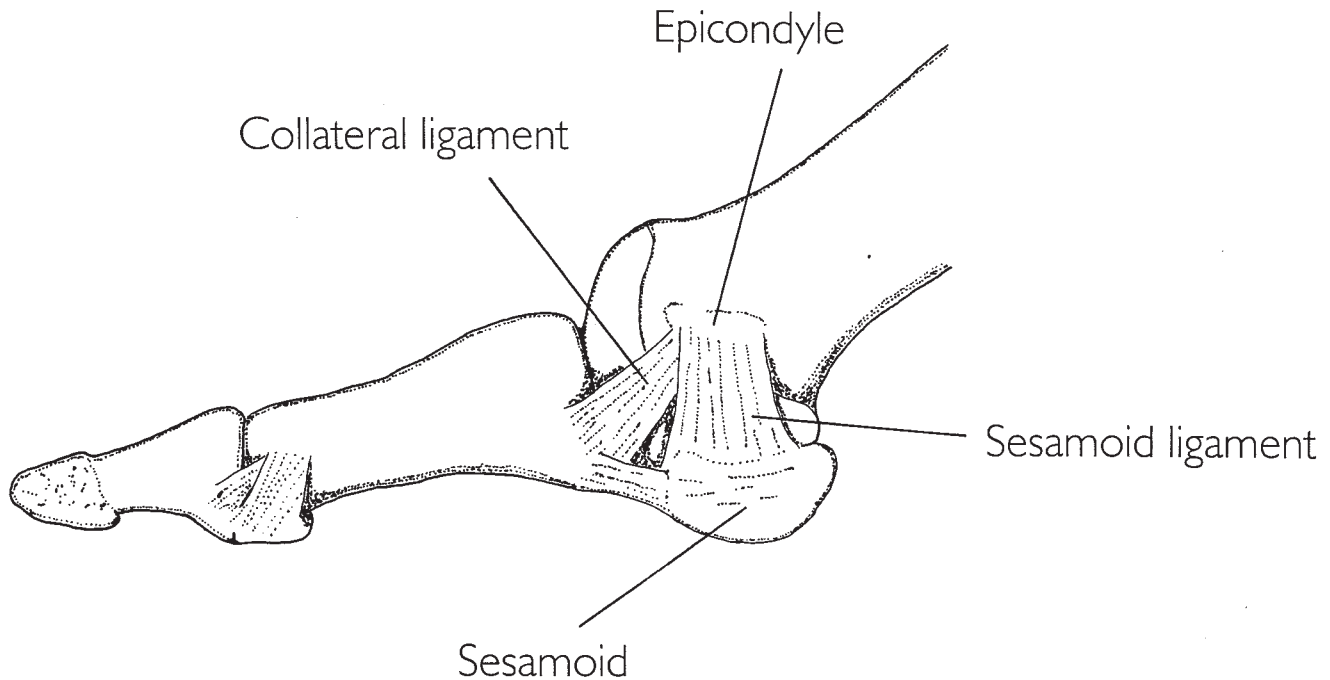


Fig. 3. Medial view of right great toe, showing location of sesamoid and collateral ligaments.

cial class. The earlier material, from the School Street and St. Peter's Street sites, likely represents a general cross section of the local population. By contrast, the later material, from the Blackfriars site, is biased toward the richer social classes. In the Medieval period, friars were dependent on financial support from lay benefactors. At death, benefactors were often buried within the friary. Burial of lay benefactors within the monastic precinct was a means of cementing the relationship between a monastic house and the family of patrons or benefactors; from the brethren's point of view, this helped secure continuity of support (Golding, 1986). Given the financial role of benefactors, it is not likely that the poorer social classes would be represented among friary burials, and documentary evidence supports this. Written sources relating to nearly 300 burials at Blackfriars friaries in the Medieval period indicate that the deceased were generally drawn from the town in which the friary was situated or its immediate locale, and were of middle-class mercantile or professional status, or else minor members of the gentry (Palmer, 1891).

METHODS

Clinically, measurement of the geometry of the foot, or radiographically of its articulations (particularly the angle of the first metatarso-phalangeal joint), plays an important role in the assessment of hallux valgus (Coughlin, 1996). However, the strategy of attempting to mimic the measurements made clinically using archaeological material was eschewed here. Firstly, in dry bones it is difficult accurately to rearticulate the components of a joint so that the angle between them can be measured reli-

ably. Secondly, it requires that both components of each joint of interest be present and undamaged, a requirement likely to reduce sample size significantly in the fragmentary and incomplete material customarily encountered by paleopathologists. Lastly, geometry of the various pedal articulations shows a fairly high degree of variation, even in subjects who are clinically normal and with no podiatric problems (Steel et al., 1980; Kusomoto et al., 1996). It may therefore be unwise to attempt to use such measurements to impose a rigid standard of normality by which individuals may be judged (Renton and Stripp, 1982). Instead of a system based on measurements, a nonmetric approach was followed.

The fundamental sign of hallux valgus is the lateral deviation of the basal phalanx upon the head of the first metatarsal. In instances in the study material where the basal phalanx was present, valgus deviation of the digit was judged as present or absent by rearticulating the bones. No angular measurements were made. In cases where this procedure indicated the presence of valgus deviation, it was noted that lateral deviation of that part of the joint surface of the metatarsal head which supported the phalanx was invariably present. Therefore, in instances where the basal phalanx was not preserved, valgus deviation of the digit was assessed through examination of the joint surface of the metatarsal head alone for presence of abnormal lateral deviation of the part of the joint surface which supported the phalanx. However, this in itself was insufficient to ascertain the presence of hallux valgus, both because of the rather subjective nature of the judgment of the presence of valgus deviation, and because of the above-mentioned observation

that the line of the great toe is somewhat variable even among normal subjects. In order to isolate a group with pathological first pedal rays, the presence of further indications, in addition to lateral deviation of the distal joint surface of the first metatarsal, was required. These further criteria were derived from dissection studies and radiographic and other imaging work carried out on modern cases of hallux valgus published in the medical literature. These bony changes, which are discussed in detail below, comprise the following: signs of lateral subluxation of the basal phalanx; indications of lateral subluxation of the sesamoid complex; and bony activity on the medial aspect of the metatarsal head, indicative either of bunion formation or traction on the medial collateral and sesamoid ligaments. For a foot to be assigned a positive score for hallux valgus, lateral deviation of the distal joint surface of the first metatarsal, plus at least one of the above three signs, was required. Evaluation of hallux valgus using these criteria requires only that the first metatarsal be present, thus maximizing sample size in fragmentary and incomplete remains. In each foot assigned a positive score for hallux valgus based on the above criteria, other pedal elements which were preserved were also examined for any associated changes.

For present purposes, only adults with at least one metatarsal preserved were studied. Adults were taken to be those for whom all pedal epiphyses had fused. Sex was determined using dimorphic aspects of the pelvis and skull (Workshop of European Anthropologists, 1980). Age at death was estimated principally using dental wear. For populations showing significant wear on the dentition, assessment of degree of wear on the molar teeth has been shown to be a reliable ageing technique for adults, outperforming other skeletal age indicators (references in Mays, 1998, 2002). Ideally, wear rates should be estimated for the population under study using juvenile remains (Miles, 1963), but insufficient juveniles were present for this to be possible in the current material. Brothwell (1963) demonstrated that wear rates changed little from Neolithic to Medieval times in Britain, and he provided a chart showing the relationship between chronological age and molar wear for use with British remains. This chart was used to age the current material. The state of closure of the cranial sutures (Perizonius, 1984) and the morphology of the pubic symphyses (Suchey et al., 1987, 1988) were used as subsidiary indicators. Osteoarthritic alterations to the hallucial metatarsophalangeal joint were scored on a presence/absence basis, using the diagnostic criteria of Rogers and Waldron (1995).

RESULTS AND DISCUSSION

Forty-seven individuals (21 males, 21 females, and 5 unsexed) from the earlier Medieval material, and 192 (125 males, 58 females, and 9 unsexed) from the later Medieval group fulfilled the criteria de-

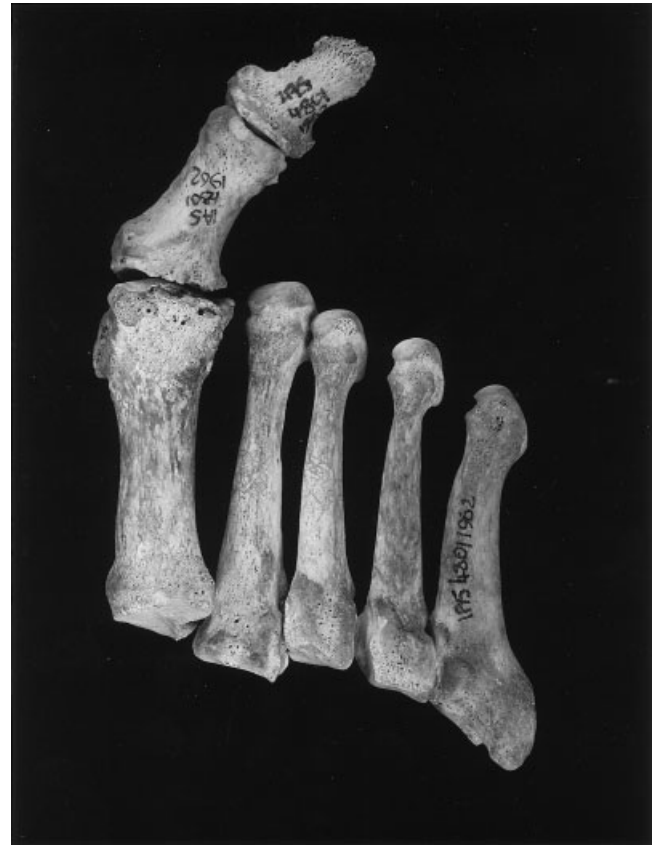

Fig. 4. Metatarsals and hallucial phalanges from Ipswich Blackfriars burial 1962, rearticulated to demonstrate hallux valgus.

scribed above for inclusion in the study. Fourteen individuals were found to show hallux valgus (Fig. 4); all were from the later group (Table 1).

Of the 14 individuals showing hallux valgus according to the current diagnostic criteria, 5 showed bilateral changes, 7 showed unilateral disease, and in 2 it was unclear whether lesions were unilateral or bilateral, as only one first metatarsal was present for observation. There are thus 19 diseased first metatarsals. The anatomical changes present in this group are considered in more detail below.

Anatomical findings in the first metatarsal head

Lateral angulation of the joint surface. Lateral deviation of the distal joint surface of the first metatarsal (Fig. 5) has been observed in modern cases of hallux valgus, both radiographically (Stein, 1938) and on dissection (Anderson, 1891; Haines and McDougall, 1954). One might argue that a metatarsal articular surface showing abnormal lateral obliquity is a cause of (or at least a disposing factor toward) hallux valgus rather than a consequence of it. However, as discussed above, it is clear that biomechanical pressure rather than congenital deformity of the metatarsophalangeal joint is the principal eliciting factor for hallux valgus. It therefore seems much more likely that, as previously suggested (e.g., Stein, 1938), the abnormal orienta-

TABLE 1. Cases of hallux valgus from Ipswich Blackfriars: itemization of presence of changes in first metatarsals used in diagnosis of disease¹

Skeleton	Sex	Age	Side	Lat dev	Sublux phal	Sublux ses	Med act	OA
0992	M	25-35	L	+	+	+	er, ex	-
			R	+	+	+	er, ex	-
1740	M	Adult	L	+	+	?	er, ex	-
1757	M	40-50	R	+	+	+	ex	+
1782	M	25-30	L	+	?	?	er, ex	-
1944	M	Adult	L	+	+	+	er, ex	+
			R	+	+	+	er	+
1962	M	22-50	L	+	+	-	er, ex	+
			R	+	+	-	er, ex	+
2411	F	Adult	R	+	+	+	er, ex	+
2458	M	21-24	R	+	+	+	er, ex	-
2499	M	Adult	L	+	+	-	er, ex	-
2537	F	60+	L	+	+	+	er, ex	+
2583	M	50+	L	+	-	+	er, ex	-
			R	+	-	-	er, ex	-
2624	M	22-25	R	+	+	+	er	-
3054	F	40-50	L	+	?	+	er, ex	+
			R	+	?	+	er, ex	-
3107	M	50+	R	+	+	-	ex	+

¹ Age, estimated age at death in years; Lat dev, lateral deviation of metatarso-phalangeal articulation; Sublux phal, bony evidence on metatarsal distal articular surface for lateral subluxation of basal phalanx; Sublux ses, bony evidence on metatarsal distal articular surface for lateral subluxation of sesamoids; Med act, bony activity on medial aspect of metatarsal head: er, erosion, ex, exostosis; OA, distal metatarsal joint surface osteoarthritis. +, change present; -, change absent; ?, no observation (part of bone missing or damaged).

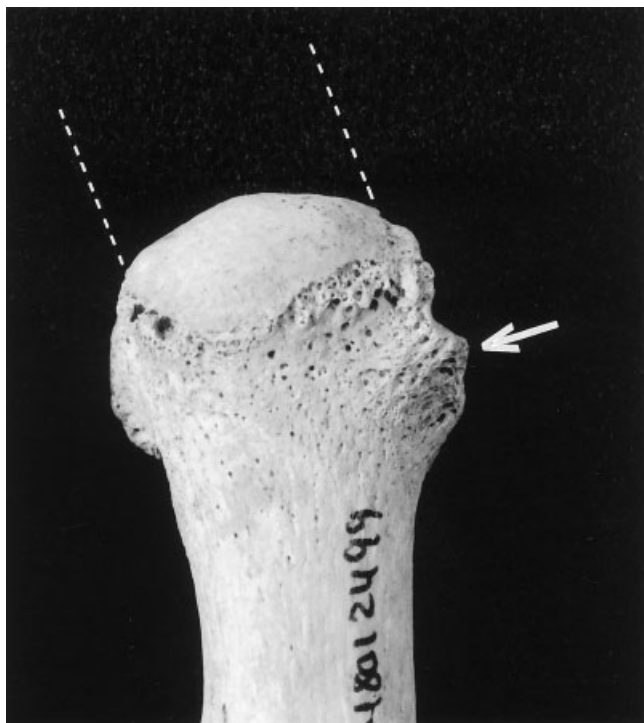


Fig. 5. Dorsal view of left first metatarsal from Ipswich Blackfriars burial 2499. There is abnormal lateral deviation of joint surface supporting basal phalanx (indicated by dotted lines). There is also large exostosis (arrow) at medial epicondyle.

tion of the articular surface generally reflects a secondary adaptive bony change in response to the altered biomechanical forces on the joint.

Lateral subluxation of the basal phalanx. In all but two of the diseased metatarsals in the cur-

rent series where the subchondral bone of the metatarsal head was sufficiently intact to permit observation, changes were seen which appeared to be a response to the valgus subluxation of the digit. The more medial parts of the joint surface which no longer articulated with the displaced phalanx lacked their normal smooth appearance, but instead had a somewhat granular or slightly roughened surface. In many instances this part was separated from the functioning articular surface by a sagittal groove (Fig. 6). These morphological changes in the subchondral bone of the metatarsal head were observed in cadaveric specimens (Haines and McDougall, 1954). It appears that they reflect thinning and degeneration of the cartilage in those parts of the joint surface which no longer have functional articulation with the phalanx; in particular, the sagittal groove appears to be an area of minimal pressure, either from the phalanx or from joint-supporting structures (Haines and McDougall, 1954).

Lateral subluxation of the sesamoids. It is clear from dissection studies that subluxation of the sesamoids in hallux valgus may lead to morphological changes in the subchondral bone of the metatarsal head. Pressure from the lateral displacement of the medial sesamoid may cause erosion and lipping of the intersesamoid ridge, and eventually the ridge may be completely smoothed out (Haines and McDougall, 1954). There was evidence for these changes in 12 first metatarsals. For example, the left first metatarsal of burial 2537 (Fig. 7) shows smoothing of the intersesamoid ridge from the medial side. Atop the remains of the ridge is an area of eburnation. This suggests that the medial sesamoid (which was not recovered) had subluxated to this

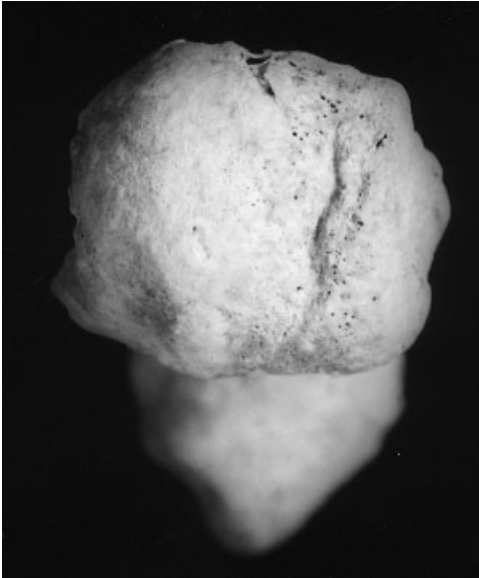

Fig. 6. Anterior view of head of right first metatarsal, Ipswich Blackfriars burial 2411. Marked sagittal groove divides joint surface. Articular surface medial to groove (at right) which no longer supported laterally subluxated basal phalanx in vivo lacks its normal smooth appearance, and instead shows somewhat granular texture.

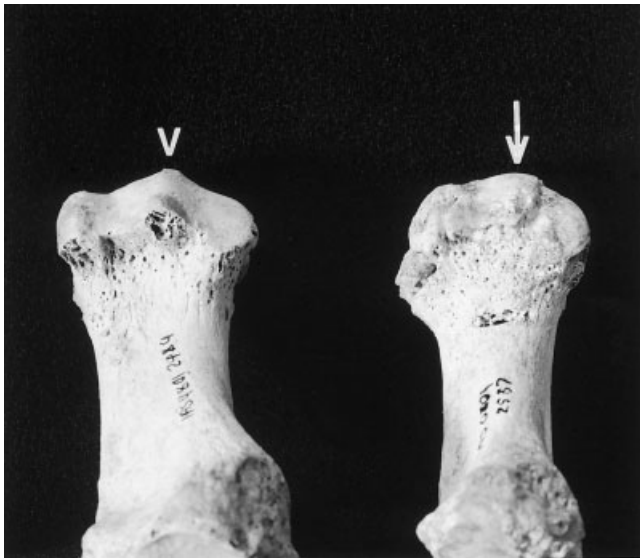


Fig. 7. Inferior surfaces of left first metatarsals from Ipswich Blackfriars burials 2484 and 2537. Bone from burial 2484 (**left**) shows normal anatomy, with prominent intersesamoid ridge (arrowhead). **Right:** Intersesamoid ridge in bone from burial 2537 (arrow) shows smoothing from medial side and lipping on its lateral margin.

position. The lateral side of the ridge is somewhat lipped.

Bony activity on the medial side of the first metatarsal head. Changes to the medial side of the head were seen in all 19 diseased first metatarsals. Exostoses and erosions each occurred in 17 bones.

Bony outgrowths on the medial aspect of the first metatarsal head were observed using radiographic (Haines and McDougall, 1954) and other imaging techniques (Schweitzer et al., 1999) in living subjects with hallux valgus. In the present examples, all exostoses represent bony extensions to the medial epicondyle (Fig. 5). Both the medial collateral and sesamoid ligaments originate at the medial epicondyle, and in hallux valgus the lateral deviation of the digit and the lateral displacement of the sesamoid complex mean that both ligaments are stretched. It therefore seems likely that the bony outgrowths observed represent an osteogenic response provoked by traction on these ligaments.

In all instances when erosions were present on the medial metatarsal head, they were situated immediately anterior to the medial epicondyle. They ranged from small, approximately circular holes (Fig. 8a), through larger, irregular erosions (Fig. 8b) to gulleys, running obliquely between the epicondyle and the margin of the articular surface (Fig. 8c). Frequently, the margins of the erosions impinged slightly upon the edge of the articular surface. All erosions showed margins of porous cortical bone except one, which had a surface of sclerotic trabecular bone. Careful observation is required to distinguish the bony erosions of hallux valgus from those due to erosive arthropathies such as rheumatoid arthritis, seronegative spondyloarthropathy, and gout. Gout, in particular, is a pertinent differential diagnosis, as the first metatarso-phalangeal joint is frequently, and often specifically, affected (Levinson, 1989). Erosions due to gout frequently have hook-like overhanging margins and may be highly destructive of the joint surface (Weinfeld and Schon, 1998; Rogers, 2000). The current lesions lack these features. Furthermore, the lesions observed in first metatarsals in the current material are highly consistent in their location (on the medial aspect of the metatarsal head, just anterior to the medial epicondyle), a feature not characteristic of lesions due to gout.

Erosion at the medial eminence was observed radiographically in living patients with hallux valgus (Haines and McDougall, 1954). It was also reported paleopathologically (Rogers and Waldron, 1995). Although its causes are unclear, pressure from an overlying bursa and thickened joint-supporting structures, pressure of footwear on the abnormally prominent metatarsal head, or chronic local inflammation seem plausible explanations.

Osteoarthritis. Nine diseased first metatarsals showed changes on the distal joint surface indicative of osteoarthritis. In all nine instances, eburnation was present. Osteoarthritic changes were observed both in the dorsal part of the joint surface which articulates with the basal phalanx (Fig. 9a), and on the plantar aspect where the sesamoid bones articulate (Fig. 9b). In addition, three further metatarsals showed marginal osteophyte formation in the absence of joint surface changes. Osteoarthritic

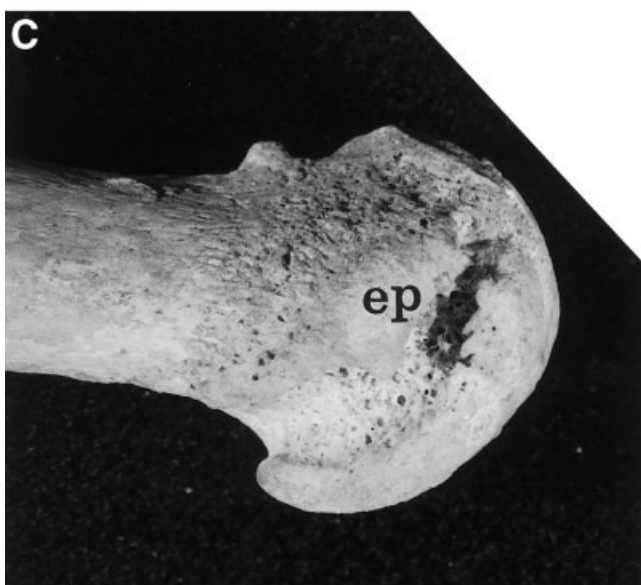
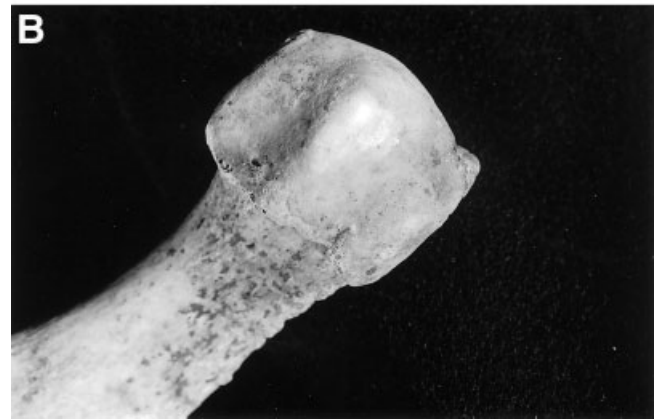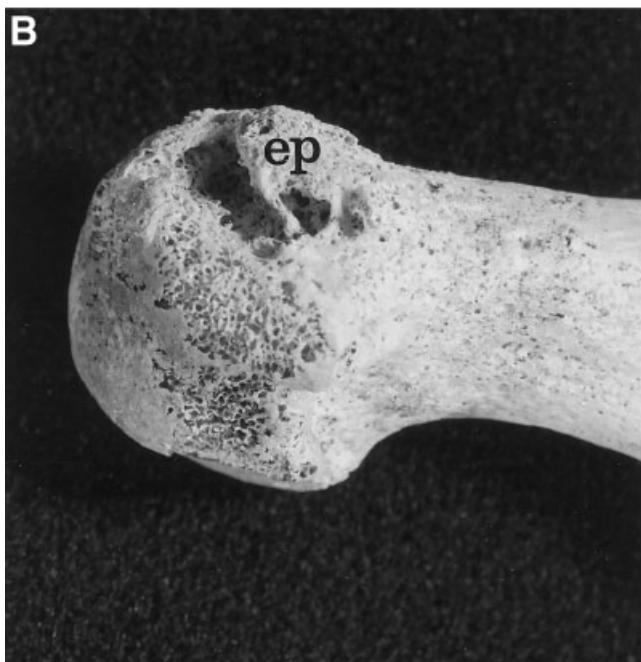
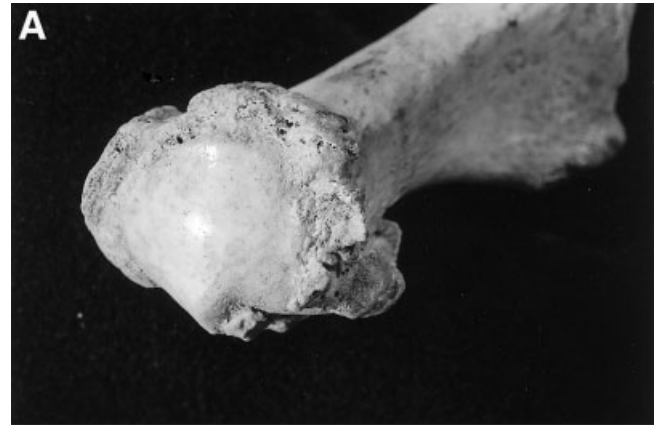

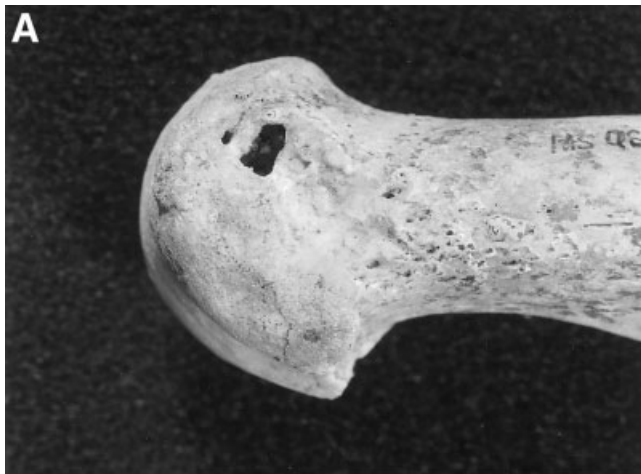
Fig. 9. Degenerative changes on distal joint surface of first metatarsal. **a:** Left first metatarsal, Ipswich Blackfriars burial 1944. Joint surface for basal phalanx shows eburnation and marginal osteophyte formation. Note also marked lateral angulation of articular surface. **b:** Right first metatarsal, Ipswich Blackfriars burial 1944, inferior view. There is a patch of eburnation on medial side of intersesamoid ridge. This indicates that medial sesamoid was subluxated laterally, so that it lay against medial side of ridge rather than in its normal location in medial plantar groove.

changes at the metatarso-phalangeal joint are a recognized complication of hallux valgus (Helfet and Greubel-Lee, 1980; Weinfeld and Schon, 1998). Although one might expect osteoarthritis to be more frequent in hallux valgus than in normally orientated metatarso-phalangeal joints, it may clearly still occur in the normal hallux. Osteoarthritis of the hallux cannot therefore of itself be used as a diagnostic indicator of hallux valgus. Hallux valgus should be diagnosed using the criteria described above, but when hallucial osteoarthritis is present

Fig. 8. Erosions of medial first metatarsal head. **a:** Right first metatarsal, Ipswich Blackfriars burial 1944, showing small erosion near joint surface margin. **b:** Right first metatarsal, Ipswich Blackfriars burial 3054. There is erosion between medial epicondyle (marked "ep") and joint surface. Epicondyle also shows bony extension. Superficial erosion of joint surface is postdepositional artifact. **c:** Left first metatarsal, Ipswich Blackfriars burial 0992. There is a large, gully-like erosion between medial epicondyle (marked "ep") and joint surface. Epicondyle shows large bony exostosis, which overhangs eroded area.

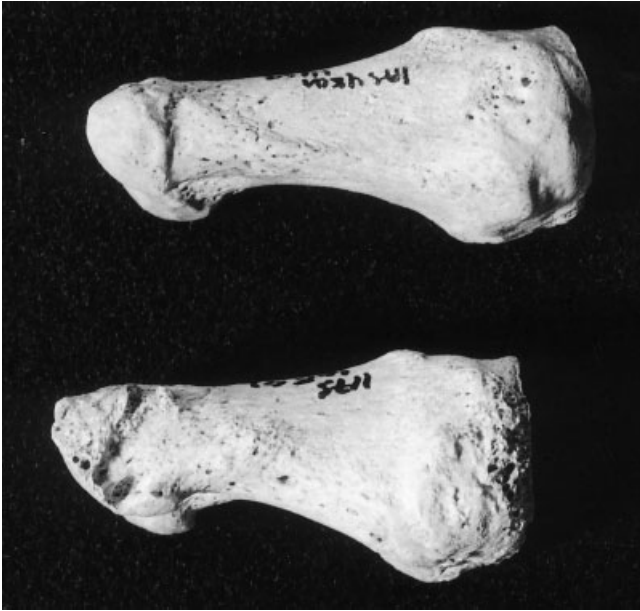

Fig. 10. Medial view of right basal hallucial phalanges from Ipswich Blackfriars burials 2458 (above) and 2583 (below). Bone from burial 2458 exhibits normal anatomy; that from 2583 shows erosion toward distal end, encroaching slightly upon distal joint surface.

in such feet, it may be a complication of that condition.

Anatomical findings in other pedal elements

Basal hallucial phalanges occasionally showed abnormal angulation of their proximal joint surfaces (Fig. 4). Osteoarthritis was also sometimes observed when changes were present on the metatarsal head.

The proximal hallucial phalanges of burial 2583 showed erosions lined with cortical bone on the medial margins of their distal joint surfaces (Fig. 10). Similar erosions were present on the lateral sides of the fifth metatarsal heads of burial 1740. Morphologically, these erosions resemble those which were seen on the medial sides of the first metatarsal heads in the present material, and they are in an analogous location. If it is accepted that the erosions on the medial metatarsal heads are associated with bunions, then perhaps the erosions at these other sites reflect bunion formation on the digit of the great toe (hallux valgus interphalangeus; Coughlin, 1996) and at the base of the fifth toe (the so-called tailor's bunion; Yale, 1980).

Observations on modern cadavers (Haines and McDougall, 1954) showed that individuals with hallux valgus may show medial deviation of the facet for the first metatarsal on the medial cuneiform, a manifestation of metatarsus primus varus. In the Ipswich material, even in normal feet, marked interindividual variation occurs in the orientation of the distal joint surface of the medial cuneiform. To control for this, left and right medial cuneiforms were compared in individuals showing unilateral hallux valgus. Of these, only one individual, burial

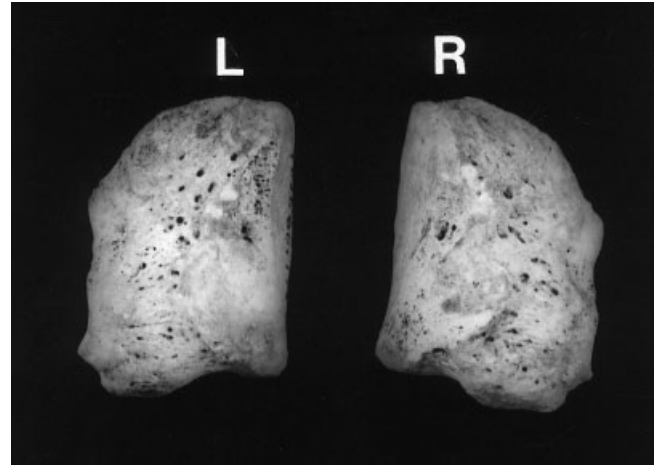


Fig. 11. Medial view of left (L) and right (R) medial cuneiforms from Ipswich Blackfriars burial 1757. Joint surface for metatarsal is more medially orientated in right bone, suggestive of metatarsus primus varus.

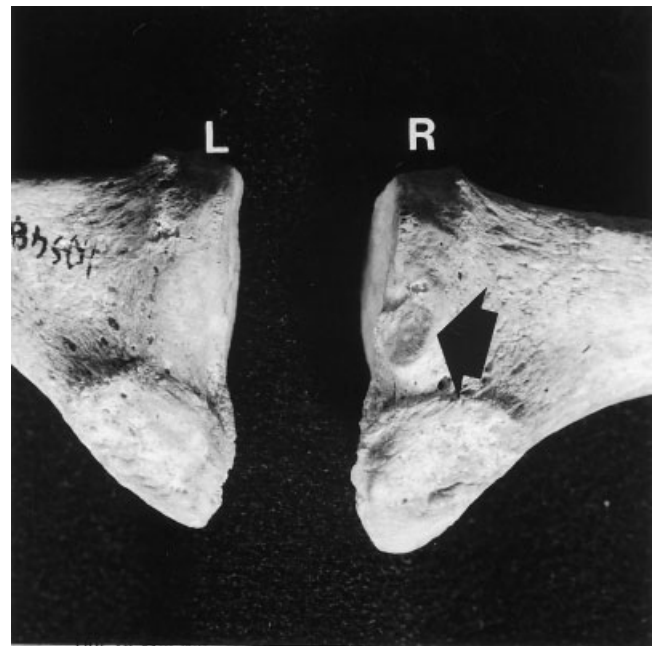


Fig. 12. Lateral view of proximal ends of first metatarsals from Ipswich Blackfriars burial 1757. L, left; R, right. Right bone shows a facet (arrow) for articulation with second metatarsal.

1757 (which showed particularly severe unilateral hallux valgus), displayed any notable asymmetry in the orientation of the distal articular surface of the medial cuneiforms. This joint surface was orientated more medially in the affected foot (Fig. 11). This is, therefore, the only individual of those exhibiting hallux valgus where the presence of metatarsus primus varus can be demonstrated osteologically. Interestingly, the affected foot of this individual also showed an articular facet between the bases of the first and second metatarsals, where none normally exists (Fig. 12). Payr (1894) suggested that this anatomical variant may be acquired due to metatarsus

primus varus, and imaging techniques visualized it in some living subjects who showed metatarsus primus varus with hallux valgus (Karasik and Wapner, 1990).

Patterning in the frequency of hallux valgus in the study material

Of the 10 adults with hallux valgus who could be more closely aged, about half appear to have been under approximately 40 years old. That relatively young adults may show the condition is consistent with observations made clinically. In patients with hallux valgus, deformity is often first noticed in adolescent or early adult life, even though most cases do not come to the attention of physicians until many years later, when symptoms become sufficiently troublesome to prompt the patient to seek medical attention (Hardy and Clapham, 1951; Piggett, 1960).

Fisher's exact test (Blalock, 1972) indicates that the difference in frequency of hallux valgus between the earlier and later groups attains statistical significance at the 5% level ($P = 0.042$). For the Blackfriars material, chi-square testing provides no evidence for a sex difference in the prevalence of the condition (chi-square = 1.76, $P = 0.19$). Given the association known to exist between hallux valgus and the use of constricting footwear, the observation that the disease was confined to the later Medieval material suggests that this population may have habitually worn such footwear, in contrast to the earlier group. This suggestion appears consistent with other evidence for Medieval footwear.

Perhaps the most important source of evidence for the form of English Medieval footwear is the large series of preserved leather shoes from archaeological contexts in London. Study of this material (Grew and de Neergaard, 1988; Pritchard, 1991) indicates that finds from 10th–11th century contexts were predominantly broad, rounded toe designs. However, in the 12th century, the popularity of styles with narrow, pointed toes increased. The popularity of the pointed-toe form seems to have waxed and waned over the succeeding two centuries, but by the end of the 14th century nearly every example in the London series was, at least to some extent, pointed-toed (Grew and de Neergaard, 1988). Documentary evidence shows that the late 14th century saw the introduction of shoes with greatly exaggerated points, called poulaines or pikes, which were often stuffed with hair or moss to preserve their shape. Indeed, many of the examples from the London series dating to the late 14th century are remarkably pointed. These were indicators of high social status, and in the mid-15th century, styles reached such extremes that legislation was passed, most probably to frustrate the excesses of the nouveaux riches, which limited the use of poulaines to the highest social ranks and also restricted their length (Grew and de Neergaard, 1988).

There is some evidence from the shoes themselves that the pointed-toe style caused podiatric problems for the wearers. From the 12th century onwards in the London series, there occur sporadic examples of shoes showing slits or holes which appear to have been made deliberately to accommodate the bunions of hallux valgus (Grew and de Neergaard, 1988; Pritchard, 1991).

The observation that hallux valgus occurred in the later but not earlier Medieval material from Ipswich seems consistent with the changing fashions in shoe form outlined above. The difference between the earlier and later material may also be a reflection of the likely higher status of the Blackfriars burials, given that possession of shoes with exaggeratedly long, narrow toes was a signifier of elevated social status. However, even in the Blackfriars material, hallux valgus, scored according to the current criteria, was fairly uncommon, being present in about 7% of adults for whom observations could be made. Perhaps most did not possess shoes of a style to cramp the feet sufficiently to precipitate the bony changes of hallux valgus. In addition, Medieval people who possessed such footwear may generally have used more comfortable shoes for everyday wear (Grew and de Neergaard, 1988). It may also be relevant that Medieval shoes had flat heels. Raised heels tend to force the toes into the end of the shoe and so, when coupled with a pointed-toe design, are particularly deleterious to podiatric health. These did not appear until the 17th century (Linder and Saltzman, 1998).

In the Blackfriars group, hallux valgus was found in both males and females, and there was no evidence of any sex difference in its prevalence (although the sample size for females was fairly small). There is thus no evidence that one sex or the other more frequently wore constricting footwear. The observation that some cases were found in adults aged in their 20s suggests that, in some instances at least, constricting footwear probably began to be used prior to adult life.

It is notable that hallux valgus in the present series was frequently unilateral (in 7 out of 12 cases where this could be ascertained). Among these cases there was no preference as to whether left or right feet were affected. Nondirectional asymmetry in hallux valgus in this group is not unexpected, given that, with handmade footwear, it is quite likely that the fit of left and right shoes of a pair should have differed.

CONCLUSIONS

The cardinal changes of hallux valgus are the lateral deviation of the basal phalanx upon the head of the first metatarsal, the lateral displacement of the sesamoid complex, and the formation of a bunion over the medial aspect of the joint. Cadaveric and imaging studies published in the medical literature describe in some detail the anatomical changes in this condition. The present work abstracts from

these works the bony manifestations of these cardinal changes in hallux valgus, and illustrates their use in paleopathologic identification of the disease. The methods described enable identification of the disease from the changes to the first metatarsal head alone. The strategy of evaluating diagnostic changes upon a single pedal element was pursued in order to maximize sample sizes in the fragmentary and incomplete material customarily encountered in paleopathology.

Given the high frequency of hallux valgus in modern populations, its prevalence in the past is of interest from the point of view of the history of podiatric health. That its cause is primarily biomechanical means that its presence may be used as a clue to the type of footwear used. This type of paleopathologic evidence may complement that from archaeological finds of the remains of boots or shoes or artistic representations of footwear. However, in most archaeological deposits, footwear rarely survives, as it was generally made from perishable materials. Artistic depictions are only available for some periods and regions, and in any event are often stylized and poorly detailed. Under many circumstances, biomechanically induced podiatric conditions such as hallux valgus may be the only evidence we have for the type of footwear used by our forebears.

Although remains of footwear from archaeological sites may help us to study changing shoe designs in the past, it is very difficult to distinguish male and female fashions. To some extent the size of the shoe can help us to determine whether it was a male or female item. However, in practice, overlap between male and female foot sizes and the unpredictable shrinkage which may occur in leather, both during interment and following recovery, may conspire to frustrate attempts to distinguish male and female fashions (Grew and de Neergaard, 1988). The study of frequencies of biomechanical podiatric conditions in skeletons may shed light on differences in footwear between the sexes.

In osteological studies of paleopopulations, investigations of the link between social status and health status have long formed an important focus (Larsen, 1997). Generally, such linkages arose via differences in nutrition, living conditions, or activity patterns between status groups. In the current case, the linkage is rather different, podiatric health being compromised in the richer social classes of late Medieval England by the use of footwear designed more for ostentatious display than for functionality. In most human societies, costume, including footwear, is a means by which individuals may display the social status they have attained or to which they aspire. Individuals may be prepared to forgo a degree of physical comfort in order to conform to the norms of dress of a social subgroup to which they wish to display allegiance. The present work indicates that this was the case in the British Medieval period; further studies relating hallux valgus to so-

cial status may reveal other instances of this in past populations.

LITERATURE CITED

- Al-Abdulwahab SS, Al-Dosry RD. 2000. Hallux valgus and preferred shoe types among young healthy Saudi Arabian females. *Ann Saudi Med* 20:319–321.
- Anderson W. 1891. Lectures on the contractions of the fingers and toes; their varieties, pathologies and treatment. *Lancet* 2:213–215, 279–282
- Barnett CH. 1962. The normal orientation of the human hallux and the effect of footwear. *J Anat* 96:489–494.
- Blalock HM. *Social statistics*, 2nd ed. London: McGraw-Hill.
- Brothwell DR. 1963. *Digging up bones*. Oxford: Oxford University Press/British Museum (Natural History).
- Coughlin MJ. 1996. Hallux valgus. *J Bone Joint Surg [Am]* 78:932–966.
- Golding B. 1986. Burials and benefactions: an aspect of monastic patronage in thirteenth century England. In: Ormrod WM, editor. *England in the thirteenth century: proceedings of the Harlaxton Conference*. Dover: Boydell. p 64–75.
- Grew F, de Neergaard M. 1988. *Mediaeval finds from excavations in London 2: shoes and pattens*. London: HMSO.
- Haines RW, McDougall A. 1954. The anatomy of hallux valgus. *J Bone Joint Surg [Br]* 36:272–293.
- Hardy RH, Clapham JCR. 1951. Observations on hallux valgus. Based on a controlled series. *J Bone Joint Surg [Br]* 33:376–391.
- Helfet AJ, Greubel-Lee DM. 1980. Acquired deformities of the toes. In: Helfet AJ, Greubel-Lee DM, editors. *Disorders of the foot*. Philadelphia: Lippincott. p 117–137.
- Hoffman P. 1905. Conclusion drawn from a comparative study of the feet of bare-footed and shoe-wearing peoples. *Am J Orthop Surg* 3:105–136.
- James CS. 1939. Footprints and feet of natives of the Solomon Islands. *Lancet* 2:1390–1393.
- Karasik D, Wapner KL. 1990. Hallux valgus deformity: preoperative radiological assessment. *AJR* 155:119–123.
- Kato T, Watanabe S. 1981. The etiology of hallux valgus in Japan. *Clin Orthop* 157:78–81.
- Kusomoto A, Suzuki T, Kamakura C, Ashizawa K. 1996. A comparative study of foot morphology between Filipino and Japanese women, with reference to the significance of a deformity like hallux valgus as a normal variation. *Ann Hum Biol* 23:373–385.
- Larsen CS. 1997. *Bioarchaeology: interpreting human behavior from the skeleton*. Cambridge: Cambridge University Press.
- Levinson DJ. 1989. Clinical gout and the pathogenesis of hyperuricemia. In: McCarty DJ, editor. *Arthritis and allied conditions: a handbook of rheumatology*, 11th ed. Philadelphia: Lea & Febiger. p 1645–1664.
- Linder M, Saltzman CL. 1998. A history of medical scientists on high heels. *Int J Health Serv* 28:201–225.
- Mann RA, Coughlin MJ. 1981. Hallux valgus—etiology, anatomy, treatment and surgical considerations. *Clin Orthop* 157:31–41.
- Mays SA. 1989a. The Anglo-Saxon human bone from School Street, Ipswich, Suffolk. *Ancient Monuments Laboratory Report* 115/89. Portsmouth: English Heritage.
- Mays SA. 1989b. The human bone from St. Peter's Street, Ipswich, Suffolk. *Ancient Monuments Laboratory Report* 101/89. Portsmouth: English Heritage.
- Mays SA. 1991. The Mediaeval burials from the Blackfriars Friary, School Street, Ipswich, Suffolk. *Ancient Monuments Laboratory Report* 16/91. Portsmouth: English Heritage.
- Mays S. 1998. *The archaeology of human bones*. London: Routledge.
- Mays S. 2002. The relationship between molar wear and age in an early 19th century AD archaeological human skeletal series of known age at death. *J Archaeol Sci* 29:861–871.
- Miles AEW. 1963. The dentition in the assessment of individual age in skeletal material. In: Brothwell DR, editor. *Dental anthropology*. Oxford: Pergamon Press. p 191–209.

- Palmer CFR. 1891. Burials at the priories of the Black Friars. *Antiquary* 23:122–126, 24:28–30, 76–79, 117–120, 265–269.
- Payr E. 1894. Pathologie und Therapie des Hallux Valgus. *Beitr Klin Med Chir* 8:1.
- Perizonius WRK. 1984. Closing and non-closing sutures in 256 crania of known age and sex from Amsterdam (AD 1883–1909). *J Hum Evol* 13:201–206.
- Piggott H. 1960. The natural history of hallux valgus in adolescence and early adult life. *J Bone Joint Surg [Br]* 42:749–760.
- Pritchard F. 1991. Small finds. In: Vince A, editor. *Aspects of Anglo-Norman London: II. Finds and environmental evidence*. London and Middlesex Archaeology Society special paper 12. London: London and Middlesex Archaeology Society. p 120–278.
- Renton P, Stripp WJ. 1982. The radiology and radiography of the foot. In: Klenerman L, editor. *The foot and its disorders*, 2nd ed. Oxford: Alden Press. p 305–399.
- Rogers J. 2000. The palaeopathology of joint disease. In: Cox M, Mays S, editors. *Human osteology in archaeology and forensic science*. London: Greenwich Medical Media. p 163–182.
- Rogers J, Waldron T. 1995. *A field guide to joint disease in archaeology*. Chichester: Wiley.
- Schweitzer ME, Maheshwari S, Shabshin N. 1999. Hallux valgus and hallux rigidus: MRI findings. *Clin Imag* 23:397–402.
- Shine IB. 1965. Incidence of hallux valgus in a partially shoe-wearing community. *Br Med J* 1:1648–1650.
- Sim-Fook L, Hodgson AR. 1958. A comparison of foot forms among the non-shoe and shoe-wearing Chinese population. *J Bone Joint Surg [Am]* 40:1058–1062.
- Steel MW, Johnson KA, DeWitz MA, Ilstrup DM. 1980. Radiographic measurements of the normal adult foot. *Foot Ankle* 1:151–158.
- Stein HC. 1938. Hallux valgus. *Surg Gynecol Obstet* 66:889–898.
- Suchey JM, Wiseley DV, Katz D. 1987. Evaluation of the Todd and McKern-Stewart methods of ageing the male os pubis. In: Reichs KJ, editor. *Forensic osteology: advances in the identification of human remains*. Springfield, IL: Charles C. Thomas. p 33–67.
- Suchey JM, Brooks ST, Katz D. 1988. Instructional materials for use of the Suchey-Brooks system for age determination of the female os pubis. Instructional materials accompanying female pubic symphyseal models of the Suchey-Brooks system. Fort Collins: France Casting (Diane France).
- Weinfeld SB, Schon LC. 1998. Hallux metatarsophalangeal arthritis. *Clin Orthop* 349:9–19.
- Workshop of European Anthropologists. 1980. Recommendations for age and sex diagnoses of skeletons. *J Hum Evol* 9:517–549.
- Yale I. 1980. *Podiatric medicine*, 2nd ed. London: Williams & Wilkins.